

Proposal for research and education: joint lectures and practicals on central nervous system anatomy and physiology

Ikuo Kageyama¹ · Ken Yoshimura¹ · Yoshihide Satoh² · Chinthani D. Nanayakkara³ · Ranjith W. Pallegama⁴ · Shin-ichi Iwasaki²

Received: 31 August 2015 / Accepted: 5 November 2015 / Published online: 30 November 2015
© The Physiological Society of Japan and Springer Japan 2015

Abstract We coordinated anatomy and physiology lectures and practicals to facilitate an integrated understanding of morphology and function in a basic medical science program for dental students and to reduce the time spent on basic science education. This method is a means to provide the essential information and skills in less time. The overall impression was that the practice of joint central nervous system lectures and practicals was an efficient method for students, which suggests that joint lectures might also be useful for clinical subjects. About two-thirds of students felt that the joint anatomy and physiology lecture on the central nervous system was useful and necessary in understanding the relationship between morphology and function, at least for this subject. One-third of students were neutral on the effectiveness of this method. However, the survey results suggest that improvements are needed in the method and timing of joint lectures and practicals. The present teaching approach can be further improved by conducting combined lectures in which the form and function of anatomic structures are presented by the relevant departments during the same lecture. Finally, joint

lecturers and practicals offer an opportunity to increase student understanding of the importance of new research findings by the present authors and other researchers.

Keywords Anatomy · Physiology · Central nervous system · Joint lectures · Practicals · Dental students · Basic medical science

Introduction

Recently, attempts have been made to improve teaching of the basic medical sciences, mainly anatomy and physiology. However, most of these efforts concern improvement of instruction during lectures and practicals [1–3]. Some authors have suggested that integrated teaching of anatomy and physiology is effective in highlighting the links between the subjects [4]. In addition, medical and dental students prefer to be taught gross anatomy through the use of dissection, but have no preference for a method of physiology instruction [5]. Finally, we consider it important to incorporate recent research findings from our departments and other groups into the lectures and practicals.

The first section of this article summarizes the results of temporally coordinated anatomy and physiology lectures and practicals in the basic medical science program at The Nippon Dental University School of Life Dentistry, Niigata, Japan, which were offered in January 2015. The goal of this instructional method was to facilitate an integrated understanding of morphology and function in a basic medical science program for dental students.

Integration of anatomy and physiology might help reduce the time spent on basic science education. This is an important concern, given the increased emphasis on

✉ Shin-ichi Iwasaki
iwasaki@ngt.ndu.ac.jp

¹ Department of Anatomy, The Nippon Dental University School of Life Dentistry at Niigata, 1-8 Hamaura-Cho, Chuo-ku, Niigata 951-8580, Japan

² Department of Physiology, The Nippon Dental University School of Life Dentistry at Niigata, 1-8 Hamaura-Cho, Chuo-Ku, Niigata 951-8580, Japan

³ Department of Basic Sciences, Faculty of Dental Sciences, University of Peradeniya, Peradeniya 20400, Sri Lanka

⁴ Division of Physiology, Department of Basic Sciences, Faculty of Dental Sciences, University of Peradeniya, Peradeniya 20400, Sri Lanka

clinical science instruction in countries such as Sri Lanka. The second section of this article introduces an example of horizontal integration of anatomy and physiology at the Faculty of Dental Sciences at University of Peradeniya, which is the center solely responsible for training dental surgeons in Sri Lanka.

The ideas discussed in this review were first presented in a symposium entitled “Possibility of joint lecture and practicals on central nervous system anatomy and physiology” at the Joint Meeting of the 120th Annual Meeting of The Japanese Association of Anatomists and the 92nd Annual Meeting of The Physiological Society of Japan, which was held in Kobe, Japan, in March 2015.

Lectures and practical training on the central nervous system: an anatomic view

In response to concerns regarding its aging population, in January 2015 the Japanese government adopted a new strategy to improve earlier diagnosis of dementia and provide better care for persons with dementia. The plan will take effect in 2017 and calls for dentists and doctors to receive training on early diagnosis of dementia [6–8]. Therefore, dentists will require additional education on the brain.

Lectures on the brain

Departments of Anatomy and Physiology at The Nippon Dental University School of Life Dentistry at Niigata have been offering instruction on the brain and central nervous system (CNS). Anatomy courses cover these topics over a period of several days and include:

1. development of the CNS and cerebral ventricle,
2. basic structure of the brain and cerebral association fibers,
3. typical functional localizations,
4. layers of the cerebral neocortex,
5. association areas of the cerebral cortex, including the speech centers Broca’s and Wernicke’s areas,
6. the basal ganglia,
7. the diencephalon,
8. the brainstem,
9. the basic structure of the spinal cord,
10. several typical examples of conducting pathways.

Practical brain course

We also teach a practical on the brain. Visual instruction is given using chalkboard instruction and PowerPoint presentations. The practical covers these topics in 2 days. On

the first day of the practical, students observe overviews of the excised whole brain, covered with the dura mater, arachnoid, and pia mater [9], and arachnoid granulations and carefully remove the covering of the arachnoid. At this time, they must identify the cranial nerves and subarachnoid arteries involving the arterial circle of Willis. After this, students are asked to draw the basal region of the brain. Then, they must carefully remove the covering of the subarachnoid arteries, except for the circle of Willis. Drawings of the lateral hemisphere of the brain are also made by the students (Fig. 1). After this dissection, we use diagrams and handouts so that students can compare textbook illustrations with the actual physical specimen. In their observations, the students must produce correlative drawings. Chalkboard instructions (Fig. 2) are more beneficial than PowerPoint presentations, as chalkboard illustrations are displayed throughout the course. The advantage of this is that students can constantly refer to them. PowerPoint presentations are usually displayed briefly and are thus easily forgotten by viewers.

On the second day, the brain is carefully removed from its brainstem by a horizontal excision at the superior colliculus. It is then excised sagittally at the longitudinal fissure of the cerebrum and divided into hemispheres. Then, the cerebellum is removed from the brainstem by excising

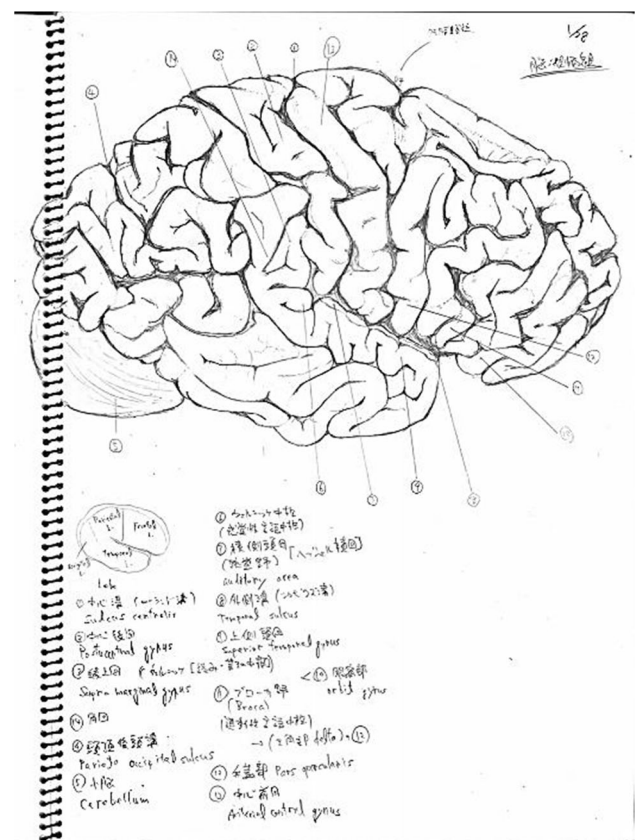


Fig. 1 Example of a student drawing, during a practical on the brain

the cerebellar peduncles, which exposes the rhomboid fossa of the fourth ventricle. The students must also observe and draw the rhomboid fossa [10]. After this, each hemisphere is sliced frontally at the anterior commissure and horizontally at the anterior–posterior commissure line. Each slice is observed and drawn. These activities are usually completed in 4–5 h.

Lectures on the historical understanding of CNS disorders

Most students are interested in CNS morphology. However, the CNS lacks morphologic characteristics and structures, unlike other organs such as muscles and vessels. Therefore, we provide lectures that are knowledge-based but also include historical information. One example discussed in our lecture is the association areas of the cerebral cortex, including the speech centers, like Broca’s area. We describe the historical background of Broca’s area and its related disorders. In 1861, the French surgeon Pierre Paul Broca described two patients who had lost the ability to speak after injury to the posterior inferior frontal gyrus of the brain. The first patient was named Leborgne. He could only produce single-syllable sounds, which he usually repeated twice in succession; regardless of the question asked him, he always responded, “tan, tan”, combined with varied expressive gestures [11, 12]. He was thus known throughout the hospital by the nickname Tan. Clinical studies of Broca’s aphasia often assume that deficits in these patients are due entirely to dysfunction in Broca’s area, thereby attributing all aspects of the disorder to this brain region. Regarding Leborgne’s hemisphere, students found degeneration in the triangular and opercular regions of the inferior frontal gyrus [11, 12]. At this time, we role-play Leborgne’s symptoms: “What is your name?” “Tan,

tan!”. Many students seem quite surprised by this activity. But when asked, “What would you do if a patient in your dental clinic presented like this?”; many students immediately appreciate the importance of understanding clinical manifestations, rather than just anatomic knowledge.

Comments

In our anatomy department, we use the above-mentioned method to provide instruction to our dental faculty. Despite our conventional, old-fashioned style (especially regarding drawings and chalkboard instruction), there are many advantages for our students. However, these methods are one-directional, and learning is passive. The new strategy developed by the government emphasizes the need for early diagnosis of dementia by dentists [6–8]; however, the instruction available in dental faculties is limited. Our CNS course provides both basic information on the CNS and extensive clinical content. Understanding the historical context of CNS disorders might contribute to extensive learning; however, future instruction will need to engage students in active learning. To urge students to shift from passive to active learning, partial introduction and integration of teaching methods such as team-based and problem-based learning should be adopted.

Current practicals and lectures on the CNS: the physiologic perspective

Physiology instruction for dental students comprises the functions of the entire body, including the cardiovascular and respiratory systems, as well as orofacial and tongue function. To cite one example, orofacial somatic sensation, gustation, mastication, jaw reflexes, swallowing, salivation, and articulation have neural mechanisms. Thus, dental students must understand neural pathways and reflex arcs. We provide instruction on sites related to orofacial function, neural pathways, and reflex arcs in the cerebral cortex, the basal ganglia, the diencephalon, and brainstem.

Cerebral cortex

The primary somatosensory and primary motor cortices of the orofacial regions lie in the lateral cortex and have a large cortical representation. Thus, orofacial motor control requires greater precision. Repetitive electrical stimulation of a certain area of the cerebral cortex induces rhythmic jaw movements in monkey, cat, guinea pig, rat, and rabbit. Rhythmic jaw movements are accompanied by coordinated, rhythmic tongue movement and secretion of saliva. Accordingly, this area has been called the cortical masticatory area [13]. Gustatory information is transmitted to the



Fig. 2 Example of chalkboard instruction, during a practical on the brain

primary gustatory cortex from the nucleus of the solitary tract via the ventral posteromedial nucleus (VPM) of the thalamus. The primary gustatory cortex is located in the insula and is related to the recognition of the intensity and quality of taste.

There are two speech areas in the cerebral cortex. Broca's area is the motor speech area and controls production of intelligible speech. Wernicke's area is the sensory speech area. It processes auditory input for languages and is important in understanding speech.

Basal ganglia

The basal ganglia comprise the caudate and putamen, the internal and external segments of the globus pallidus, and the pars reticulata and pars compacta of the substantia nigra. Anatomically, the substantia nigra does not seem to be part of the basal ganglia, as it is present in the midbrain. Physiologically, however, the substantia nigra is included in the basal ganglia. The internal segment of the globus pallidus and pars reticulata of the substantia nigra is the output nucleus of the basal ganglia and projects to the thalamus. The pars compacta of substantia nigra dopaminergic neurons projects to the caudate and putamen. Degeneration of dopaminergic neurons in the substantia nigra pars compacta causes Parkinson disease. The cardinal symptoms of Parkinson disease include akinesia, bradykinesia, tremor, and rigidity. Symptoms associated with dentistry are tongue tremor, mastication disorder, and dysphagia.

Diencephalon

The VPM of the thalamus transmits somatosensory information from the orofacial region to the primary somatosensory cortex. The VPM is also the secondary relay nucleus of gustation.

The lateral hypothalamus contains a feeding center, and the ventromedial hypothalamus contains a satiety center. The acute nucleus produces the hypothalamus hormone and controls secretion of the anterior pituitary hormone. The paraventricular nucleus and supraoptic nucleus produce posterior pituitary hormone. The preoptic nucleus and anterior hypothalamic area are involved in the control of body temperature.

Brainstem

Masticatory rhythm is generated by the central pattern generator (CPG) in the brainstem (Fig. 3). The CPG is driven by the cortical masticatory area and somatic sensation from the orofacial region. Motor commands for mastication are sent to the trigeminal motor nucleus from

the CPG. Activities in jaw-closing motoneurons consist of rhythmic alternation of depolarization (excitation) and hyperpolarization (inhibition) coincident with the jaw-closing and jaw-opening phases, respectively. In contrast, activities in jaw-opening motoneurons consist only of rhythmic excitation during the jaw-opening phase [13]. Localization of the CPG in the brainstem is still unclear.

The mesencephalic trigeminal nucleus receives proprioceptive information from muscle spindles in jaw-closing muscles and the periodontal ligament. This nucleus is involved in the jaw-jerk (masseteric monosynaptic) reflex and periodontal masseteric reflex. The main sensory trigeminal nucleus receives tactile and pressure sensation from the orofacial region. The spinal trigeminal nucleus receives somatosensory information from the orofacial region. The spinal trigeminal nucleus caudalis, in particular, is important as the relay nucleus of pain. The spinal trigeminal nucleus oralis (SpVO) and interporalis (SpVI) contain excitatory interneurons to jaw-opening motoneurons in the jaw-opening reflex. The supratrigeminal nucleus is dorsal to the trigeminal motor nucleus and contains inhibitory interneurons to jaw-closing motoneurons in the jaw-opening reflex [14]. The nucleus of the solitary tract receives gustatory and visceral sensation and is involved in coordinating the cardiovascular and respiratory systems. The CPG of swallowing is located in the nucleus of the solitary tract [15].

The red nucleus (RN) is an oval column of cells extending from the caudal margin of the superior colliculus into the caudal diencephalon. The RN projects bilaterally with contralateral dominance to the SpVo and to the SpVI [16]. Our previous research showed that the jaw-opening and masseteric monosynaptic reflexes were both modulated by stimulation of the RN [17, 18]. We found that stimuli applied to the RN or lesions of the RN influence the

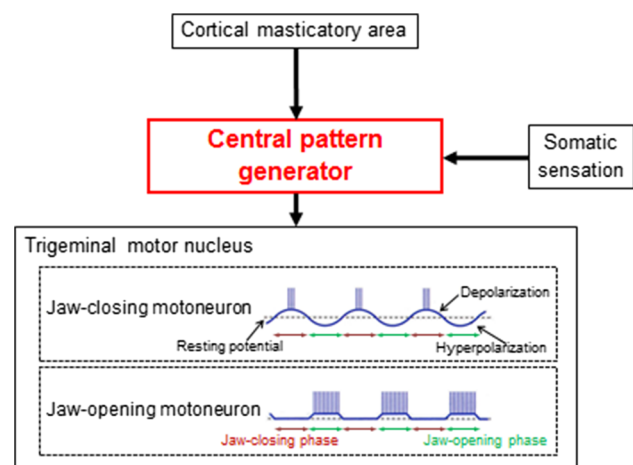


Fig. 3 Activities of jaw-closing and jaw-opening motoneurons induced by the central pattern generator during mastication

rhythmic jaw movements induced by repetitive electrical stimulation of the anterior part of the cortical masticatory area [19, 20]. Recently, we have demonstrated that the swallowing reflex is suppressed by stimulation of the RN [21].

The motor trigeminal nucleus contains the jaw-closing and jaw-opening motoneurons. The jaw-opening motoneurons innervate the lateral pterygoid muscle, the anterior belly of the digastric muscle, and the mylohyoid muscle. The facial nucleus innervates the facial muscle. The hypoglossal nucleus innervates the tongue muscle and geniohyoid muscle.

The vestibular nuclear complex (VN) lies in the floor of the fourth ventricle and extends from levels rostral to the hypoglossal nucleus. The VN projects to the SpVo and to the SpVI [22]. We previously reported that jaw-opening and masseteric monosynaptic reflexes were modulated by stimulation of the VN [23, 24], and that the VN is involved in controlling jaw movements [25–27].

The superior salivatory nucleus (SSN) innervates the submandibular and sublingual glands. The inferior salivatory nucleus innervates the parotid gland. We reported that ionotropic NMDA and non-NMDA receptors evoke an excitatory response in the SSN neurons [28, 29] and that SSN neurons receive cardiac and/or respiratory inputs [30].

Understanding the location and function of these sites in three dimensions is extremely challenging for dental students because the structure of the central nervous system is complicated. Anatomic knowledge is thus essential for all physiology lectures.

Physiology practicals

We taught five items (see below). Because of animal welfare concerns, we stopped using animals for such training 6 years ago. All training is done using human subjects. CNS physiology remains an educational challenge.

1. Electrocardiography and heart rate variability (recording and component analysis of electrocardiograms, instant heart rate variability due to respiration),
2. Blood pressure measurement (differences in blood pressure on the left and right sides, differences in blood pressure by altitude, blood pressure increases caused by cold and pain),
3. Masticatory efficiency,
4. Measurement of bite force and jaw-closing muscle surface electromyography (measurement of bite force, a jaw-closing muscle surface electromyogram during food mastication),
5. Sensation of skin and oral (pain regions of the tongue and oral mucosa, two-point threshold, discrimination

of planting sites in teeth, discrimination of the thickness of the occlusal substance).

Possibility of joint CNS lectures and practicals in anatomy and physiology

A recent survey revealed that the time allotted for lectures in anatomy and physiology is drastically decreasing in medical and dental schools because students are required to study an increasing number of subjects. However, knowledge of anatomy and physiology is essential, especially for clinicians. No one would trust a surgeon who lacks knowledge of anatomy and physiology. Medical and dental students should learn anatomy and physiology because it is critical for them and their colleagues in co-medical disciplines. The practice of joint lectures and practicals might be an efficient method for such study. The next section of this review will discuss the possibility of joint lectures and practicals on CNS anatomy and physiology.

Research of joint lectures and practicals for students

Joint anatomy and physiology lectures and practicals on the CNS were offered to 95 Japanese second-year dental students in January 2015 at the Nippon Dental University School of Dentistry at Niigata, Japan. After the lecture and practical, a ten-item questionnaire was given to the students (see below). Student responses to items 1–7 are shown in Fig. 4. Responses to items 8–10 are indicated below.

1. Were the joint CNS lectures and practicals (LP) useful?
Student responses are summarized in Fig. 4a.
2. Did you understand the joint LP?
Student responses are summarized in Fig. 4b.
3. The joint LP is necessary.
Student responses are summarized in Fig. 4c.
4. Were you interested in the joint LP?
Student responses are summarized in Fig. 4d.
5. What is your opinion of the method used for the joint LP?
Student responses are summarized in Fig. 4e.
6. Would you recommend the joint LP to students next year?
Student responses are summarized in Fig. 4f.

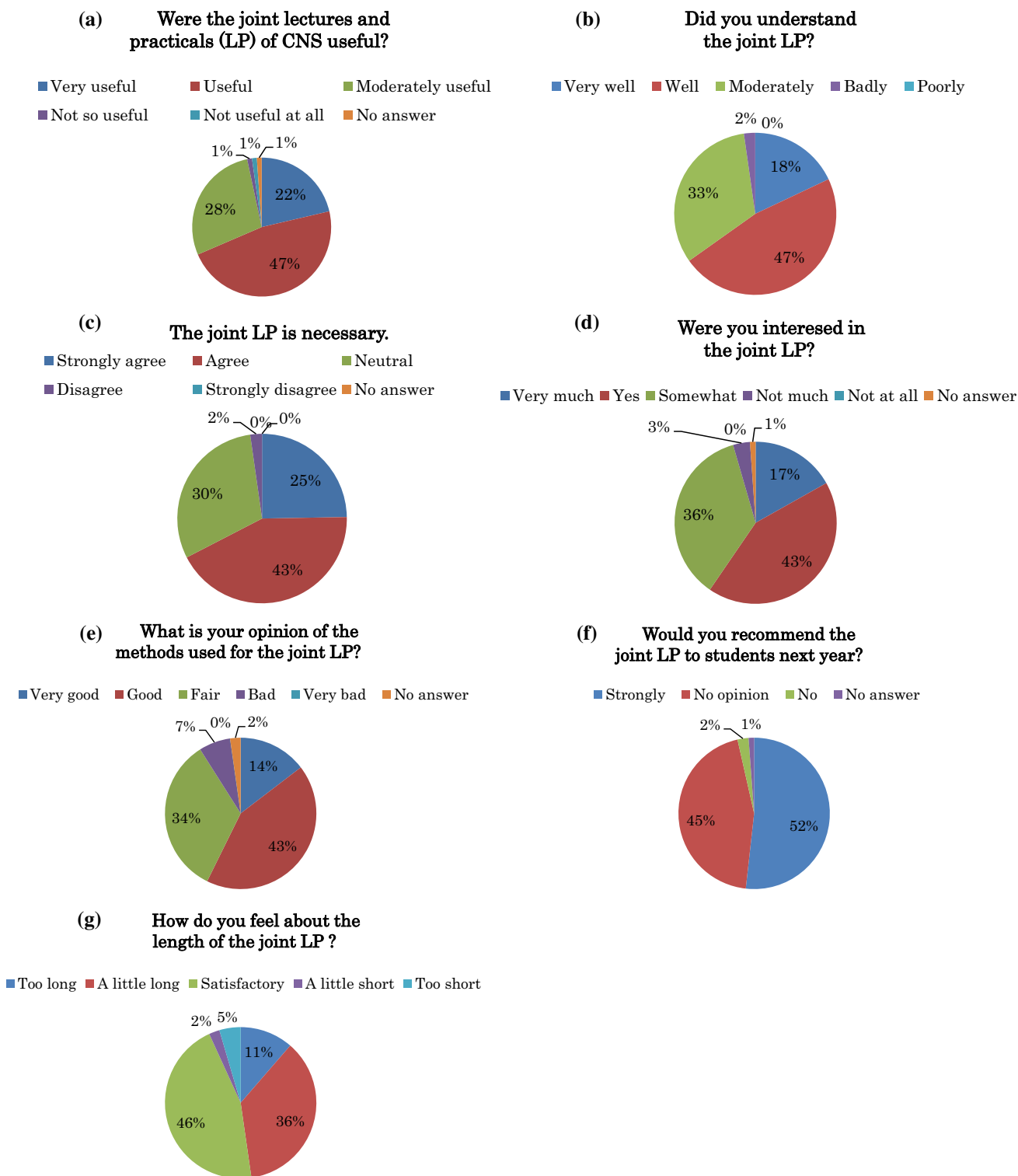


Fig. 4 Answers to research on joint lectures and practicals for students. **a** Student responses to the question, “Were the joint CNS lectures and practicals (LP) useful?”. **b** Student responses to the question, “Did you understand the joint LP?”. **c** Student responses to the statement, “The joint LP is necessary”. **d** Student responses to the

question, “Were you interested in the joint LP?”. **e** Student responses to the question, “What is your opinion of the methods used for the joint LP?”. **f** Student responses to the question, “Would you recommend the joint LP to students next year?”. **g** Student responses to the question, “How do you feel about the length of the joint LP?”

7. How do you feel about the length of the joint LP?

Student responses are summarized in Fig. 4g.

8. What was the most useful part of the joint LP?

Positive comments from students were as follows;

- “We understood the difference between CNS anatomy and physiology.”
- “We understood the relationship between anatomy and physiology and their relationship to other medical subjects.”
- “We were interested in the neural conducting pathways, including the afferent and efferent pathways.”
- “We understood the relationship between basic medicine and clinical medicine.”

9. What was lacking in the joint LP?

How can we address these deficiencies?

Negative comments from students were as follows:

- “The allotted time was too long.”
- “Need breaks between lectures and practicals.”
- “Need clearer explanations for each part.”

10. Other comments from students were as follows;

- “We enjoyed attending the joint LP due to the precise and cheerful explanations.”
- “The joint LP is one of the most efficient methods to understand the CNS.”

Comments

Knowledge of anatomy and physiology is fundamental for medical and dental clinicians and for co-medical specialists. The time allotted for lectures in anatomy and physiology is drastically decreasing in medical and dental schools due to the necessity of including other medical instruction. The present method might be a means to provide the essential information and skills in less time. The overall impression was that the practice of joint CNS lectures and practicals was an efficient method for students, which suggests that joint lectures might also be useful for clinical subjects.

Current trends in neuroanatomy instruction in Sri Lanka

Human anatomy, which includes gross anatomy, embryology, and neuroanatomy, is a crucial component of the basic sciences and is relevant to students in health sciences. Since the time of Aristotle, the study of the relationship between form and function, such as anatomy and

physiology, has been an integral component of health science education. Likewise, neuroanatomy and neurophysiology are the cornerstones of our understanding of the nervous system and its disorders.

In the traditional curriculum, anatomy, physiology, and biochemistry are taught as lecture-intensive, departmentally based, independent courses. The traditional anatomy curriculum consists of independent courses in gross anatomy, neuroanatomy, histology, and embryology. There is little interrelationship in teaching and learning across subjects. This method of teaching has come under considerable criticism. The many flaws in such an approach have been highlighted by medical educators. Disjointed approaches to teaching, repetition, overlap of subject areas, and disunity of subject matter confuse students, which leads to disinterest. As a result, the larger perspective is not well understood. One medical educator maintained that “knowledge learnt in isolation is rapidly forgotten” [31, 32].

Medicine and dentistry are rapidly advancing. Students are thus required to master new technology and new subjects. In recent years, this has increased pressure on teachers in basic sciences to reduce time spent in learning these subjects. The amount of time dedicated to anatomy and physiology, and therefore to neuroanatomy and neurophysiology, has substantially decreased. To overcome these challenges, educators around the world strongly advocate integrated instruction for undergraduate medical education. Integration is defined as organization of teaching content to interrelate or unify subjects frequently taught in separate academic courses or departments. Integration aims to give students a holistic rather than a fragmented outlook on their studies [33]. It abandons traditional discipline-based teaching and learning activities. Topics can be presented in a more meaningful way. It can decrease student confusion regarding form and function of the system concerned, its diseases, and their diagnosis and treatment. Integration can be done in two ways. Horizontal integration links disciplines taught at a given stage in a conventional curriculum, e.g., anatomy, physiology, and biochemistry. Vertical integration links subjects conventionally taught at different stages in the curriculum, e.g., anatomy, pathology, and surgery.

The Bachelor of Dental Surgery course at the University of Peradeniya, Sri Lanka, spans eight semesters and 4 years. The first two semesters offer a course in basic medical sciences (Fig. 5). In semesters 3 and 4, students learn paraclinical subjects, e.g., pathology, microbiology, and pharmacology. The last four semesters are set aside entirely for clinical training. In recent years, the traditional, discipline-based, lecture-intensive basic medical sciences curriculum was replaced with a system-oriented, horizontally integrated curriculum. Course content is organized into 18 course units, mostly based on body systems, e.g.,

the circulatory system, respiratory system, gastrointestinal system, and host defense. Neuroanatomy and neurophysiology are taught within the course units named Nervous System (central and peripheral nervous systems) and Special Senses (vision, hearing, smell taste, etc.). Course content was defined, learning outcomes were developed, and course content is now delivered by lectures, practicals, tutorials, and supplementary activities. At the end of the semester, students are evaluated using tools such as multiple-choice questions, short-answer questions, and an objective, structured, practical examination.

Lectures on topics such as organization of the nervous system, spinal cord, brain stem, cerebral hemispheres, cerebellum, and autonomic nervous system are conducted in an integrated manner by the departments concerned, mainly anatomy and physiology. This integration gives students a holistic rather than a fragmented outlook on their studies. This teaching approach could be further improved by conducting combined lectures in which the form and function of these anatomic structures can be presented during the same lecture by the different relevant departments.

Neurophysiology instruction in Sri Lanka: present and future

Expansion of instruction in clinical sciences has decreased the time and resources devoted to basic medical sciences. However, constructively aligned, outcome-based education is promoted in Sri Lanka as a general educational policy. To introduce teaching strategies that make learning more student-centered, a qualitative study explored student opinions on the inclusion of combined neuroanatomy and neurophysiology classes. Student responses revealed that they favored such an approach and foresee many advantages. A combined approach to teaching neuroscience might facilitate outcome-based education.

Year 1	Pre clinical
Year 2	Para clinical
Year 3	Clinical
Year 4	Clinical

Fig. 5 Outline of the Bachelor of Dental Surgery course at the University of Peradeniya, Sri Lanka

The Faculty of Dental Sciences at University of Peradeniya is the only institution that trains dental surgeons in Sri Lanka. The present curriculum spans eight semesters. The first two semesters include 18 courses, which integrate the content traditionally taught under general anatomy, general physiology, biochemistry, and dental anatomy. Among those, four courses cover neuroscience content. Neurophysiology content includes the organization and function of peripheral nerves, physiology of somatic sensations including pain, autonomic nervous function, reflexes and their supraspinal control, cortical, cerebellar, and brain stem control of motor functions, neurophysiology of mastication, swallowing, speech, and special senses, and limited coverage of higher functions. Teaching–learning process (TLP) involves lectures that impart knowledge, practical classes for students to practice clinical examination, and tutorial classes for evaluating problems. Although courses are integrated, individual classes are confined to either anatomy or physiology. To make the TLP more student-centered, a qualitative study evaluated student opinions on the inclusion of combined anatomy and physiology classes.

Methodology

A captive audience of 80 first-year dental students responded to a pretested, self-administered questionnaire. Eight items explored opinions on the possible inclusion of combined anatomy and physiology classes for neuroscience instruction. Before administration, the students were given an introduction to the nature of such classes.

Results

Students want challenging and novel learning experiences but preferred a few combined sessions at the outset, as they were concerned about possible pragmatic issues. They expect planning and adequate preparation before lessons. Such approaches may facilitate learning, memory, interactions, relationship building, and formation of visual images and provide a holistic approach to patient problems, thereby breaking the monotony of learning (Table 1).

Comments

Expansion of instruction in clinical sciences has increased demands for resources and time in curricula and decreased time devoted to basic sciences (Fig. 6). A constructively aligned, outcome-based education is promoted in Sri Lanka as a general policy in education. However, student clinical competencies (intended learning outcomes) are not limited to a single discipline. Therefore, combined classes may make TLP more student-centered and better engage

Table 1 Students’ opinions in relation to potential joint classes

	Yes	No	Not sure	No response
More student centered	42	30	16	12
Improved understanding	80	6	11	3
Facilitate interaction	67	13	15	5
Facilitate holistic approach towards patients	78	9	7	6
Break monotony in learning	87	3	6	4

Percentages of reported responses

students. Although the idea of combining the teaching of neuroanatomy and neurophysiology is not new, such practice has not been reported in Sri Lanka [34]. In such a combined model, aligning intended learning outcomes, teaching content, TLP, and assessments is more practical (Fig. 7). Educators recommend this type of constructive alignment when planning teaching programs [35]. It prevents repetition and information overload and hence increases what can be achieved within a limited curriculum time. This provides better opportunities for problem-based or task-based learning, during which the teacher can be the facilitator. It enables vertical integration of curricula [36] by allowing discussion of some clinical content early in training and relevant content in basic science during clinical training (Fig. 8). However, the need for new teaching materials, rehearsals, and careful planning and time management are challenges to be addressed.

Conclusions

Temporally coordinated lectures and practicals in anatomy and physiology were offered at The Nippon Dental University School of Life Dentistry, Niigata, during December 2014. A questionnaire survey completed by students after the coordinated lectures and practicals showed that they had a highly positive impression of the program. About two-thirds of students felt that the joint anatomy and physiology lecture on the CNS was useful and necessary in understanding the relationship between morphology and function, at least for this subject. One-third of students were neutral on the effectiveness of this method. However, the survey results suggest that improvements are needed in the method and timing of joint lectures and practicals. We believe it is effective if the joint lectures and practicals in anatomy and physiology include information on new research findings from our departments and at other universities.

In the Faculty of Dental Sciences of the University of Peradeniya, Sri Lanka, lectures on topics such as organization of the nervous system, spinal cord, brain stem, cerebral hemispheres, cerebellum, and autonomic nervous system are conducted in an integrated manner by the

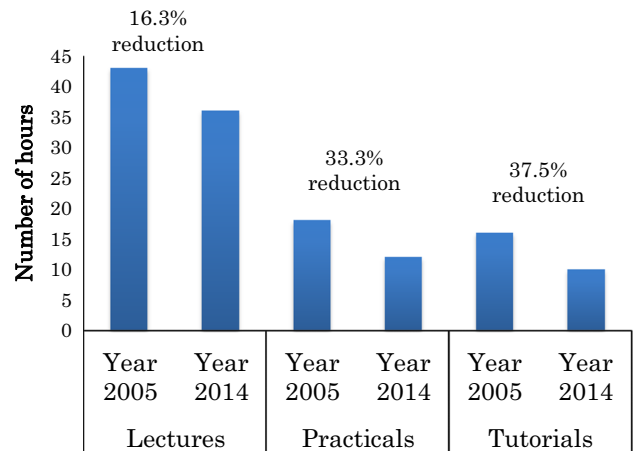


Fig. 6 Reduction of hours devoted to lectures, practicals, and tutorials on neurophysiology instruction in the BDS curriculum during a recent 10-year period in Sri Lanka

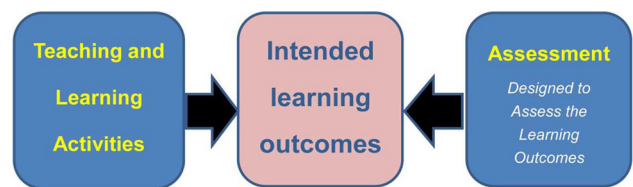


Fig. 7 A model of outcome-based education through constructive alignment

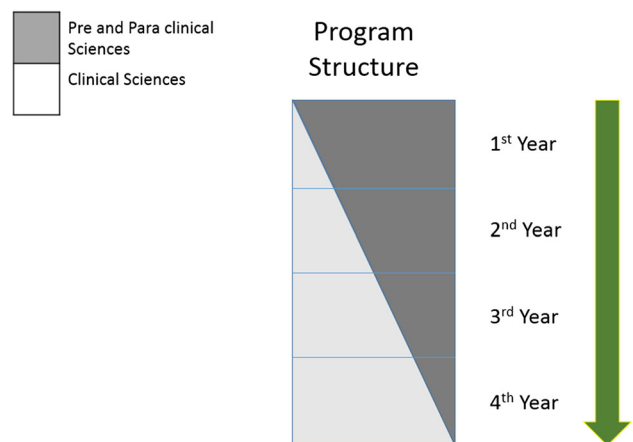


Fig. 8 Simple model of a program structure that enables vertical integration

departments concerned, mainly anatomy and physiology. This approach can be improved by conducting combined lectures in which the form and function of these structures is presented during the same lecture by the relevant departments.

Acknowledgments The authors are grateful to the staff of the Department of Anatomy at The Nippon Dental University School of Life Dentistry, Niigata—especially Guest Professor Dr. Katsuji Kumaki—for their valuable comments.

Compliance with ethical standards

Conflict of interest The authors declare that they have no conflicts of interest.

References

- Krontiris-Litowitz J (2009) Articulating scientific reasoning improves student learning in an undergraduate anatomy and physiology course. *Life Sci Educ* 8:309–315
- Dobson JL (2013) Retrieval practice is an efficient method of enhancing the retention of anatomy and physiology information. *Adv Physiol Educ* 37:184–191
- Mattheis A, Jensen M (2014) Fostering improved anatomy and physiology instructor pedagogy. *Adv Physiol Educ* 38:321–329
- Harden RM (2000) The integration ladder: a tool for curriculum planning and evaluation. *Med Educ* 34:551–557
- Olowo-Ofayoku A, Moxham BJ (2014) Comparisons between the attitude of medical and dental students toward the clinical importance of gross anatomy and physiology. *Clin Anat* 27:976–987
- Dementia to strike 1 in 5 elderly Japanese by 2025. January 8th, 2015 *Asahi Shimbun*. http://ajw.asahi.com/article/behind_news/social_affairs/AJ201501080032
- Japan to tackle rise in dementia patients to 7 million in 2025. January 8th, 2015. Quoted from the article on the newspaper “Mainichi Daily News”, Japan
- Better life for dementia sufferers. February 5th, 2015 *Japan Times*, Japan. <http://www.japantimes.co.jp/opinion/2015/02/05/editorials/better-life-for-dementia-sufferers/#.VYi1U1Litm5>
- Standring S (2008) Section 4 head and neck, chapter 27 intracranial region. In: Standring S (ed) *Gray’s anatomy*, 40th edn. Churchill Livingstone, Elsevier, New York, pp 423–434
- Jackson A, Lee J (2008) Section 3 neuroanatomy, chapter 16 ventricular system and subarachnoid space. In: Standring S (ed) *Gray’s anatomy*, 40th edn. Churchill Livingstone, Elsevier, New York, pp 237–245
- Broca P (1861) Perte de la Parole-ramollissement chronique et destruction partielle du lobe anterieur gauche du cerveau. *Bull Soc d’anthropol* 2(1):235–238
- Dronkers NF, Plaisant O, Iba-Zizen MT, Cabanis EA (2007) Paul Broca’s historic cases: high resolution MR imaging of the brains of Leborgne and Lelong. *Brain* 130(Pt 5):1432–1441 **Epub 2007 Apr 2**
- Nakamura Y, Katakura N (1995) Generation of masticatory rhythm in the brainstem. *Neurosci Res* 23:1–19
- Sumino R (1971) Central neural pathways involved in the jaw opening reflex in the cat. In: Dubner R, Kawamura Y (eds) *Oral-facial sensory and motor mechanisms*. Appleton-Century-Croft, New York
- Jean A (2001) Brain stem control of swallowing: neuronal network and cellular mechanisms. *Physiol Rev* 81:929–969
- Godefroy JN, Thiesson D, Pollin B, Rokyta R, Azerad J (1998) Reciprocal connections between the red nucleus and the trigeminal nuclei: a retrograde and anterograde tracing study. *Physiol Res* 47:489–500
- Satoh Y, Ishizuka K, Murakami T (2003) Facilitation of the jaw reflexes by stimulation of the red nucleus in the rat. *Brain Res* 978:51–58
- Satoh Y, Yajima E, Ishizuka K, Nagamine Y, Iwasaki S (2013) Modulation of two types of jaw-opening reflex by stimulation of the red nucleus. *Brain Res Bull* 97:24–31
- Satoh Y, Ishizuka K, Murakami T (2006) Modulation of cortically induced rhythmic jaw movements by stimulation of the red nucleus in the rat. *Brain Res* 1087:114–122
- Satoh Y, Ishizuka K, Murakami T (2007) Changes in cortically induced rhythmic jaw movements after lesioning of the red nucleus in rats. *Brain Res* 1165:60–70
- Satoh Y, Tsuji K, Tsujimura T, Ishizuka K, Inoue M (2015) Suppression of the swallowing reflex by stimulation of the red nucleus. *Brain Res Bull* 116:25–33
- Buisseret-Delmas C, Compoin C, Delfini C, Buisseret P (1999) Organisation of reciprocal connections between trigeminal and vestibular nuclei in the rat. *J Comp Neurol* 409:153–168
- Satoh Y, Ishizuka K, Murakami T (2009) Modulation of the jaw-opening reflex by stimulation of the vestibular nuclear complex in rats. *Neurosci Lett* 457:21–26
- Satoh Y, Ishizuka K, Murakami T (2009) Modulation of the masseteric monosynaptic reflex by stimulation of the vestibular nuclear complex in rats. *Neurosci Lett* 466:16–20
- Satoh Y, Ishizuka K, Murakami T (2010) Modulation of cortically induced rhythmic jaw movements in rats by stimulation of the vestibular nuclear complex. *Neurosci Res* 68:307–314
- Satoh Y, Yajima E, Nagamine Y, Ishizuka K, Murakami T (2011) Effects of neck muscle activities during rhythmic jaw movements by stimulation of the medial vestibular nucleus in rats. *Brain Res Bull* 86:447–453
- Satoh Y, Ishizuka K, Yajima E, Nagamine Y, Iwasaki S (2012) Neuronal activities of the vestibular nuclear complex during mechanically induced rhythmic jaw movements in rats. *Brain Res Bull* 89:86–91
- Oskutyte D, Ishizuka K, Satoh Y, Murakami T (2004) Ionotropic NMDA receptor evokes an excitatory response in superior salivatory nucleus neurons in anaesthetized rats. *Auto Neurosci* 110:98–107
- Ishizuka K, Oskutyte D, Satoh Y, Murakami T (2008) Non-NMDA and NMDA receptor agonists induced excitation and their differential effect in activation of superior salivatory nucleus neurons in anaesthetized rats. *Auto Neurosci* 138:41–49
- Ishizuka K, Oskutyte D, Satoh Y, Murakami T (2010) Multi-source inputs converge on the superior salivatory nucleus neurons in anaesthetized rats. *Auto Neurosci* 156:104–110
- Harden RM, Laidlaw JM (2012) *Essential skills for a medical teacher: an introduction to teaching and learning in medicine*. Churchill-Livingstone, Edinburgh
- Harden RM (2000) The integration ladder: a tool for curriculum planning and evaluation. *Med Edu* 34:551–557
- Joglekar S, Bhuiyan PS, Kishore S (1994) Integrated teaching—our experience. *J Postgrad Med* 40:231
- Farmer TW, Krigman MR (1967) Relations with neuroanatomy and neurophysiology in teaching. *Neurology* 17(8 Pt 2):47–48
- Biggs J, Tang C (2011) *Teaching for Quality Learning at University*. McGraw-Hill and Open University Press, Maidenhead
- Dick MLB, King DB, Mitchell GK, Kelly GD, Buckley JF, Garside SJ (2007) Vertical Integration in Teaching and Learning (VITAL): an approach to medical education in general practice. *Med J Austral* 187:133–135